

STRUCTURAL YOGA THERAPY RESEARCH PAPER

ANKLE INVERSION INJURY

June 3, 2006

Robert N. Cory Ph.D.

500 CYT, Certified Structural Yoga Therapist

email: pinesyoga@att.net

917 533-8233

Robert earned a Ph.D. in bio-medical sciences and has published several research papers in the field of neuropharmacology. He did his post-doctoral work at the CNRS in Montpellier, France and Cornell University Medical Center in New York City. He pursued hatha yoga training since a young age pursuant to a stint as a competitive gymnast. In the past ten years he studied primarily Iyengar Yoga under the tutelage of Tao Porchon Lynch, Aadil Palkhivala and Genny Kapuler. He was certified as a 200 hour teacher by Tao in 2002. In 2004 he pursued his 500 hour yoga teacher certification in Allahabad, India with the Himalayan Institute. He received certification in 2003 from Mukunda Stiles as a Structural Yoga Therapist. He currently teaches and practices in New York City, Long Island and Virginia Beach.

Supervised by Mukunda Stile

Table of Contents

<i>Case Studies</i>	3
1.a. Case Study One – Initial Interview - (Jo Anne) February 15, 2005	3
1.b. Physical Assessment	4
1.c. Summary of Findings – Jo Anne.....	5
1.d. Recommendations.....	5
1.e. Refinement of Initial Recommendations and Results of Recommendations	6
1.a. Case Study Two – Initial Interview (Linda) – March 27, 2005	9
1.b. Physical Assessment.....	9
1.c. Summary of Findings - Linda	10
1.d. Recommendations.....	11
1.e. Refinement of Initial Recommendations and Results of Recommendations	12
2.a. Name and Description of Condition	14
2.b. Gross and Subtle Body Symptoms	14
2.c. Related Challenges	16
3. Ayurvedic Assessment	16
Ayurvedic-based Yoga Recommendations.....	17
4. Common Body Readings/Findings	18
5. Contraindicated – Modify or Eliminate	18
6. General Recommendations	18
Therapeutic/Free of Pain:.....	18
Stabilize the Situation:	19
Maintenance:	19
7. Questions and Answers from www.yogaforums.com	19
Knock Knees	19
Weak Ankles	19
Ankle Iversion/Eversion.....	20
Foot Injury – Tight IT Bands.....	20
Ankle Supination (Inversion)	20
Ankle Eversion	22
8. References	23
Internet References.....	23
9. Appendix	24
Palm Tree Vinyasa.....	25

I examined and followed two female middle-aged clients with longstanding ankle and foot injuries. This injury was of particular interest to me because I have suffered from a chronic ankle inversion injury in the past two years. I have had two assessments with Mukunda that focused on this type of injury. As these case studies bear out and I have seen with myself, these types of injuries often entail compensatory modifications in posture that effect the hip and leg muscles.

Case Studies

1.a. Case Study One – Initial Interview - (Jo Anne) February 15, 2005

Jo Anne is in her late 40's and is the owner and manager of a yoga studio and is a 200-hour certified yoga instructor. She is not currently actively involved in teaching yoga. Most of her time is occupied with managing the studio. She describes her self as having playful, childlike tendencies.

Jo Anne has a long history of ankle and foot injuries that have required changes in her asana practice and more generally in her lifestyle. She underwent left foot arthroscopic surgery in March 2002 to treat bone spurs. Subsequently during the years 2002-2003 she had three severe right ankle inversion injuries. The injuries came about from 1) jumping off boulders in a landscape garden, 2) slipping on a stone slab and 3) stepping in a hole. The injuries eventually resulted in tearing of the right lateral ankle ligaments – she believes they were the talofibular ligaments. (Ligaments in this area consist of the anterior and posterior talofibular and calcaneofibular ligaments.) In March 2003 she had surgery on the right lateral ankle area to reconnect the torn ligaments. The surgery consisted of a modified Brostrom Procedure. This is a procedure frequently used to treat ballet dancer injuries and involves an anatomic reconstruction of the lateral ankle ligaments. As a result of the surgery on the two ankles she has developed longstanding but different issues in both ankles. The left ankle is habitually “stiff and weak”; the right ankle is excessively mobile. When standing on the left ankle, for example in tree posture, she feels pain and is unable to support the posture without placing a hand on the wall. She reports that the left foot arch collapses.

In March 2003 she had a private assessment with Mukunda at YogoLoft in Charlottesville, VA. Mukunda's findings were: a hip external rotation over 90 degrees for right and left sides and internal hip rotation normal range. He recommended strengthening of the tibialis posterior and tibialis anterior, erector spinae, internal hip rotators, left QL and lower quadriceps; stretching the lower hamstrings, the fascial band of the ankle and the iliotibial band.

In recent months (prior to Feb 2005) she had developed what appears to be a cyst in the left side knee area. She feels pain on either side of the left patella. The right knee is OK. She had for a while suffered from chronic migraine headaches emanating from the left side of her head and feels a spreading aura to the left eye, back of neck and left side of the body.

Jo Anne has tried to maintain a regular meditation practice over the years. She has found it very helpful in dealing with life challenges. She has recently had difficulty maintaining that practice but she is still dedicated to it in her heart.

1.b. Physical Assessment

Jo Anne is a high-energy generally optimistic woman. She is happily married, however she is facing problems with a son who suffers from depression and a terminally ill mother. I have known her for two years as the owner of a studio where I teach. She completed a yoga teacher-training program in which I taught part of the curriculum and I observed her personality and her practice closely during the duration of that program. My assessment of her began after the completion of our student –teacher relationship.

Postural analysis revealed a right shoulder slightly lower than the left. The scoliometer reading indicated a very slight 1-2 degree lumbar left curve. There was no deviation in the thoracic spine. Left leg was 1 inch shorter than the right. Client has pronounced knock-knees and hyper-extended knees. There was significantly more mobility in the left knee than the right knee both in forward movement of the tibia and rotation below the knee. The hyperextension of the left knee was more pronounced than of the right knee.

The SI test was complicated by her unsteadiness while standing on the left foot. I had her balance by placing a hand on the wall. There was no abnormality indicated in the SI test, which I repeated 4 times.

	2/15/05	8/30/05		2/15/05	8/30/05
Ankle	ROM L/R	ROM L/R		MT L/R	MT L/R
Dorsiflexion	15/20			3/4.5	4/4
Plantar flexion	45/50			5/5	5/5
Eversion	20/25			3/4	5/4*
Inversion	40/60	40/60		2.5/4	3.5/4.5*
Supine Hip					
Psoas MT				1.5/3	4/3*
Sartorius MT				3/2	4/3*
External rotation	85/75	75/65			
Internal rotation	35/35	32/30			
Adduction	50/50	48/50			
Hip Prone					
External rotation	65/75	70/65		3/4	4/3
Internal rotation	30/32	35/35		2/1	2/1
Hip extension	15/15			4/2	4/4*
Gluteus Max. MT	0.5/1	1/1			

* Significant change from 2/15/05 measurement

1.c. Summary of Findings – Jo Anne

Strengthen	Stretch	Release
Right Peroneus longus & peroneus brevis	Right tibialis posterior	
Tibialis anterior		
Tensor fascia lata, gluteus minimus, ant. gluteus medius	Gluteus maximus, deep 6 hip external rotators	Tensor Fascial Lata
Post. Gluteus medius (hip abductor)	Hip adductors	
Left iliopsoas, right sartorius		
Right hamstrings		
Gluteus maximus		

Notes:

Ankle eversion and dorsiflexion muscles, particularly on the right side need to be strengthened to protect against excessive inversion. Client has excessive hip external rotation and relatively less ROM in the hip internal rotators.

For knock-knees strengthen abductors and stretch adductors.

Client has weak left hip flexors and weak right hip extensors.

Need to release a tight TFL.

Client shows overall imbalance in hip extensor/flexor groups

1.d. Recommendations

February – March 2005

I saw this client on a weekly basis and made recommendations in the initial part of our work together. She took my physical assessment result to her physical trainer to work on her weak areas. In particular they emphasized core work and hip flexion.

From the Joint Freeing Series:

To strengthen the foot eversion and dorsiflexion muscles (peroneus longus, peroneus brevis, tibialis anterior) and stretch the primary inversion muscle (tibialis posterior): Dorsiflexion with eversion, initially 10 times each foot. Increasing to 20 repetitions over the next few weeks. Hold the eversion position for 30 sec increasing to 1 minute.

To strengthen the internal hip rotators and abductors: Starting with legs separated. Adduct the leg while rotating internally at the hip. Keep the foot in mild eversion rather than inversion to avoid countering the first exercise above. To emphasize the abduction over the adduction aspect, raise the leg on the abduction and release the leg down on the adduction.

Asanas:

Stretch and release the TFL/IT band in leg position Gomukhasana. Lean back on to hands and hold. Deep breath to release.

For hyperextended knees: Virabhadrasana I and II on a chair. Lift off the chair and hold for 1 minute then increasing to 3 minutes in the next few weeks. Work rotations from the hips not the knees.

Also employed a bound Uttansana with blocks to give her a sense of space between the upper thighs and to tone the abductors. She held a block in between the upper thighs and between the feet. The upper thighs had a strap to assist holding the block. She held for 5 min. This was repeated 3 times per week. After blocks are released she stood in Tadasana holding the impression of the now absent block between the thighs. She found this reshaping image helpful in working towards awareness of her knock-knee condition.

To strengthen hip extensors (gluteus maximus, hamstrings) do Sunbird with bent knee leg lifts. Start with 5 repetitions on each side, increasing to 10 over the next few weeks.

To strengthen hip flexors – do Navasana (Boat posture) with bent knees.

1.e. Refinement of Initial Recommendations and Results of Recommendations

June – August 2005

Refinements to the recommendations were given in this period.

June 2005

Through May Jo Anne was making progress on the exercises given above. She felt stronger in her weak left foot and was able to stand on it in tree for 30 sec. In June she was weighed down with personal problems with her son who has a worsening depression. She has cut back on her practice while dealing with these issues.

August 2005

Jo Anne has shown substantial improvement in a number of areas. During the summer she was able to return to a more dedicated practice and to concentrate on the SYT exercises given to her and to her physical training.

Hip external rotation ROM was decreased somewhat bilaterally. Internal ROM rotation remained the same. Muscle testing showed increase strength in foot/ankle eversion on both sides. The previously weaker left side was now stronger than the right side. Inversion muscles were stronger on both sides as well with more strengthening on the previously weak left side.

Psoas and sartorius muscles showed substantial strengthening. The gluteus maximus remains weak.

The hip extension test revealed increase strength on the right side. The left side remained unchanged in strength.

Based on these results the following recommendations were made on August 30.

Do the Joint Freeing Series methodically and slowly with the breath. If time or energy is a factor break it up into 2 parts and alternate days.

For hip rotators - particular internal rotation:

From the JFS do extra repetitions of the inner/outer hip rotations - bring the leg across the ground and then back. You can lift the contra-lateral hip and lean into the internal rotation to deepen the action as you bring the leg across. Don't lift the legs for now to lessen the involvement of adductors/abductors and to deepen the use of the hip rotators. You can eventually start lifting the leg in a 3:1 ratio to bring the adductors/abductors back into the picture. Also try inhaling on the internal rotation to emphasize strengthening - this is contrary to the usual breath in the JFS but may work for you right now.

For the gluteus maximus:

Do Locust with alternate legs. Don't lift the upper body. Lift alternate legs with knee bent at a right angle. You can put a weight on the hamstring to increase muscle strength for the hip extensors (both hamstrings and gluts).

For iliopsoas and sartorius - hip flexors:

Do Boat (Navasana) with bent knees keeping the upper body rigid and drawing the knees into the chest. Place the hand on the ground for stability, i.e. don't try to balance.

Do downward dog with some knee flexion and emphasize drawing the chest towards the thighs on the exhalation. This is akin to boat but standing up. This will strengthen the hip flexors.

For knock knees

Follow Mukunda's advice to work both Warrior I and Warrior II looking to hold for 5 min. You can widen the stance in the lateral plane. Always work the rotation from the hip socket and not from the knee or foot.

In general to address your out of body feeling I recommend you connect with the breath for every asana, slowly and don't get ahead of the breath. You might try Ujjayi sometimes if that helps with concentration. Always listen to the feeling in your body as you move and link it with the breath.

September 8, 2005:

Jo Anne is doing a two week Ayurvedic retreat with Pancha Karma at a Deepak Chopra Center in Arizona. I will follow up with her upon her return.

October 6, 2005:

Email to *Mukunda and his response in italicas*

From: Robert Cory <rcory@att.net>
Date: October 5, 2005 10:44:39 AM EDT
To: Mukunda Stiles <yogimukunda@comcast.net>
Subject: Ayurvedic consultation ques.

Mukunda,

One of my case study clients, Jo Anne, who you had seen, went for an Ayurvedic Retreat at Deepak Chopra's place recently. She is one of my clients with chronic ankle and hip instability issues. Recently she has felt burned out and is dealing with a sick son and a dying mother. She is up every night from 1 to 4 pm and is lacking REM sleep.

Dr. Simon at DC's place ascertained that she is pure pitta with a vata imbalance and also a raised kapha. They said there is barely a digestive fire. They want her to reduce vata through diet and asana.

Prior to panchakarma they did 3 days of rasayana oil treatments to prepare her. She says she tolerated the pancha karma well but on the ride home the plane sent her vata into more imbalance (I suspect the prospect of coming home to her family issues didn't help.) They also gave her triphala herb to improve digestion. In Norfolk she is seeing another Ayurvedic consultant, VJ Stallings who is modifying the herbal remedies at this time.

She has little energy for anything but the most gentle asana work, not surprising considering the low agni (yogically, I assume the prana vayu is weak as well).

I've given her a variation of the JFS for her ankles and hips, she is wondering what asanas might lower vata. I'm not sure how to proceed here. She needs to learn to move prana but is mired in depleted energy in the lower chakras. I don't view the asanas as specifically addressing ayurvedic imbalance. I think the way the asanas are practiced is much more important in that regard. I'm wondering if pitta stimulating pranayama such as agni sara would be appropriate at this stage.

- *Give her gentle vinyasas such as Palm Tree (see appendix). I believe I gave it there. It is not easy to learn from the flyer attached, after you have it, give it to her. Also do repetitious asanas with gentle ujjayi pausing and moving pausing and moving, etc. rolling bridge 10X, for instance. That type of practice. Yoni mudra definitely. - Mukunda*

I'm wondering if her sitting in mediation is working, she does it every day and sits for awhile. I'm concerned about her lack of sleep, maybe preparing the mind with yoga nidra or deep relaxation techniques not might be better for her. On the other hand if she is finding peace in her sitting practice, whether its true mediation or not, I don't want to disrupt that.

- *Agree your thinking is solid. - Mukunda*

I'm seeing her tomorrow prior to finishing my notes on her for the draft paper. I'd like to address

some of her latest concerns and she specifically asked if I would get feedback from you. Anything comments you might have would be appreciated.

Robert

October 7, 2005

I met with Jo Anne and listened to her concerns about lack of sleep. We did asana (Tadasana Uttanasana, Downward Dog) with great attention to full body awareness. I asked her to move the awareness with the breath, systematically to different parts of her internal body. In each location we brought energy and 'intelligence' to that part of the body. Following this we prepared a well supported seated pranayama position that kept her out of discomfort. I asked her to use this supported seated posture for nadi shodhana prior to sleep, starting with the right nostril. To address right nasal blockage problems I told her it was OK to do jala neti prior to the evening nadi shodhana. She could start with just 6 repetitions and build from there. I recommended she sleep on her right side to keep her left nostril flowing during the night. On the next visit I will present the Palm Tree Vinyasa series that Mukunda suggests.

1.a. Case Study Two – Initial Interview (Linda) – March 27, 2005

Linda is in her late 50's and works in the healing arts. She is certified as a Massage Therapist, NM Therapist, Reiki Master, Cranio-sacral Therapist and has just completed training for Yoga Teaching at the 200-hour level. Starting in the early 1970's she lived for 10 years in Guru Maharaji's Miami ashram. She worked as a community coordinator for his various ashrams in this country. Around the same time she had three or four right ankle inversion injuries. She wrapped her ankle in Ace bandages in order to provide support for walking. Again on April 12, 2005 she had another right ankle injury while walking in shoes. She currently feels significant pain on the left side leg from the medial arch of the foot up to the left knee and left groin. She has received some acupuncture treatment for this, which brings about intermittent relief from the left side pain. She is also being treated by a chiropractor for a reverse cervical neck curve. This arose from three different auto accidents in which she suffered anterior, posterior and lateral whiplash injuries. She also maintains a daily meditation practice and sits in a way that exacerbates inversion of the right ankle.

She suffered emotional trauma prior to living in the ashram. She was kidnapped and almost murdered. Her husband was murdered.

1.b. Physical Assessment

Linda is a quiet and contemplative person. She is a sensitive yoga teacher and likes to teach restorative yoga. She has a slight build and appears somewhat frail.

Postural analysis indicates that the right arm is closer to the waist than the left arm. The right shoulder is 2 inches higher than the left shoulder. She can't stand alone on the left foot without wall support. The scoliometer reading indicates a 9-degree right lumbar curve. There could exist a mild scoliosis in

the lumbar region. The SI test is within normal range with a 1 to 1.5 inch drop on either side. SI results were consistent in three tests. While supine the legs were even when the inner malleoli were touching.

	3/27/05	8/405		MT L/R	MT L/R
Ankle	ROM L/R	ROM L/R			
Dorsiflexion	10/12	12/12		4/4	4/4
Plantar flexion	78/82	80/80		4/4	4/4
Eversion	25/10	35/30 *		4/4	4/4
Inversion	47/57	45/55		4/4	4/4
Supine Hip					
Hip flexors/ MT (90 deg)	115/125	120/120		2/4	3/3*
Flexion MT (100 deg)				1/4	3/3*
Psoas MT				1/3	3/3*
Sartorius MT				1/4	4/3*
Trunk flexion bent knees				1	4*
Trunk flexion extend legs				1	4*
Knee Flexion MT				3/1	3/3*
Gluteus Maximus MT				0.5/0.5	0.5/0.5

- significant change

1.c. Summary of Findings - Linda

Strengthen	Stretch	Release
Right Peroneus longus & peroneus brevis	Right tibialis posterior	
R/L Tibialis anterior	R/L gastrocnemius, soleus	
Right side Gluteus maximus	Tensor fascia lata, gluteus minimus, ant. gluteus medius	
Left iliopsoas and rectus femoris		
Gluteus maximus and hamstrings		

Right Ankle eversion and bilateral dorsiflexion muscles need to be strengthened to protect against excessive inversion. Muscle testing indicated weak left hip flexors and weak trunk flexors. Strengthening of these is indicated. Gluteus Maximus was weak. Internal hip rotators were weaker than the hip external rotators

1.d. Recommendations

April 12, 2005

For right lumbar curve:

Locust and cobra twisting to the right. This brings the lumbar right curve towards (left) neutral and develops muscles needed to pull the spine towards neutral and lengthen muscles pulling the spine right. Finish with some straight locust. Practice locust with bent knees vs. straight legs. Start with 3 to 5 repetitions per session. With strength increase this to 10. Be mindful of incorporating the breath.

Parsvottasana – (Side of Hip Stretch) – Start facing wall by going halfway down and use hands on wall for support. Compare twisting over the extended left leg and then extended right leg. Start by holding 1 minute and gradually increase to 2-3 min.

For ankle:

As mentioned above she maintains a daily meditation practice. Her seated posture however exacerbates inversion of the injured right ankle. I showed her how to sit in a supported Sukkhasana high on blankets and wrapping a blanket under her knees, feet in mild dorsiflexion. Another option is modified Siddhasana with the right ankle on top in dorsiflexion pressing into the left adductor. Keep the inside heel moving up and the toes moving down. In any case avoid plantar flexion and inversion of the right foot while meditating.

For weak hip flexors (daily):

Adho Mukha Svanasana modified (downward facing dog), bend knees and bring abdomen towards the thighs contracting the hip flexors. Release and contract several times. Incorporate this into your regular practice of this asana

As demonstrated: Modified Navasana (boat), keep lumbar spine in mild lordosis (don't collapse lower back). Flex to the thighs, with hands behind knees for support but do not pull with the hands. Use the hip flexors to bring the chest towards the thighs. Practice with both legs, knees bent, one leg knee bent, and eventually straighten the legs.

Left side psoas strengthening: A few times per week, as shown, lean back onto forearms and abduct legs and externally rotate. Favor left leg lifts over right 3 to 1.

To strengthen gluteus maximus (daily):

Sunbird with bent knees and then pulse lift the bent knee. Work both sides equally. Other options are: Setu Bandhasana (bridge) making sure to contract gluts. Also Locust will help strengthen the gluts – see above.

To release plantar flexors and inversion muscles.

Practice active dorsiflexion and eversion. Do with soles of feet on the wall. For eversion pull the little toes towards you – only 20 degrees movement here is usual – start with 10 repetitions and increase as comfortable.

Try calf stretches by placing balls of a feet on a blanket or wedge and lean forward with a bent knee to you feel the tightness in the calf. Use breath to help relax.

To release the tibialis posterior which originates on the upper half of the posterior tibia/fibula and inserts at the bottom of the foot from the medial aspect see a bodyworker for massage and deep tissue manipulation. The release of the tibialis posterior and strengthening of the tibialis anterior will begin to stabilize the right ankle, which has seen repetitive inversion injuries.

1.e. Refinement of Initial Recommendations and Results of Recommendations

August 4, 2005

Linda had a vertigo episode this summer for a few weeks. She stopped all asana practice and mediation. When the vertigo lessened she started a practice low to the ground. One month ago she began taking classes again.

Re-measure SI and found it to be normal. She was able to stand un-assisted on her left foot in tree – a major improvement.

Significant increase in eversion ROM. Improvement in all hip muscles strength except gluteus maximus.

Now work on bilateral strengthening of psoas, sartorius and hip flexors to avoid over strengthening one side.

For hip flexors – Downward dog with emphasis on drawing thighs to abdomen. Boat posture with knees bent.

Glut. Maximus – Locust with bent knee alternating legs. Use weights on the lifting leg. Bridge posture with sandbags.

October 6, 2005

From: Robert Cory [mailto:rncory@att.net]
Sent: Thursday, October 06, 2005 9:43 AM
To: Mukunda Stiles
Cc: Fawn Deturk
Subject: Chakra work

Met with Linda at her studio. Fawn DeTurk, another SYT student accompanied me to observe. Linda recently completed a 1 week YogaTherapy course at Yogaville. She enjoyed the course but incurred knee pain from sitting all week on the floor with almost no block or cushion support available. The knee pain stopped after returning home.

She has spent more time taking care of her ailing father recently and this has interrupted her asana and meditation practice frequently. Nevertheless she reports feeling good physically.

Her seated meditation practice consists of the mantra ‘so-hum’, which she drops eventually to “ride the wave of her breath”. She reports that during meditation the energy on the left side of her neck vibrates and is disturbing her practice. The vibrations migrate to her left ear.

She reported occasional right SI discomfort not to the point of calling it pain. That wasn't present now and the SI test was normal on both sides. Re-taught her the SI exercises developed by Mukunda.

We started off doing an asana practice to relieve the frustration she has felt about not being to perform an uninterrupted practice recently. I used the asana work to review the points delineated in previous meetings. The practice began in Tadasana with variations taken from the work of Krishnamacharya (via Srivatsa Ramaswami). From the Tadasana series we did tree pose variations with the raised foot in dorsiflexion, downward dog with hands against wall and head supported on a cushion, then Virab. II with the back foot supported on the wall.

During the standing postures the following recommendations were condensed: Do not collapse into the lateral arch of the feet, instead lift from the lateral arch and the lift from the center of the foot (this keeps both the lateral and medial arches lifted and prevents the inversion tendency for Linda), lengthen the spine with the breath to remove the lateral spine curve so that the center of gravity drops through the peroneal space and not to either side of the hip.

We the practiced seated posture for pranayama. I had her sit on a high meditation cushion in sukkhasana, the feet dorsiflexed, the crossing of the shins centered in front of the middle of the perineum. She was instructed to find the center of the sitz bones, ascend the anterior spine to the inside of the upper sternum without tightening the abdominal muscles. She drew her arms back with the hands resting behind the knees towards the pelvis so as to allow the scapula to adduct which opened the upper chest. She lifted the body briefly with her hands and drew the sitz bones together to provide more lift than is acquired when the sitz bones are spreading (this was an instruction I took from Iyengar in the recent Intensive I attended in Estes Park). All of this resulted in a much more active seated posture than Linda is accustomed to having. The importance of this became evident when we practiced pranayama.

- *THIS IS essentially mula bandha not moving bones they are immobile. - Mukunda*

She did simple wave breath and immediately closed her eyes, which rolled up into her sockets. We could see that she immediately ascended to the higher chakras even though the energy was disordered in the lower chakra levels. To keep her more present in the lower chakras and in the gross body, I asked her to practice the pranayama with her eyes open. After wave breath, without kumbhaka, I taught her the shitali pranayama as recommended by Mukunda. She enjoyed this breath but I insisted she practice for 2 weeks with her eyes open so as not to jump to the higher energy states without recruiting the lower chakras first. Fawn and I agreed that the jumping from the lower to higher states might cause the disordered energy she is experiencing in the neck area. The prana is ascending rapidly and out of control. Linda's vata tendencies lead her to jump rapidly out of the physical body into a more ethereal state. Today's asana and pranayama practice were directed to keep her grounded in the lower chakras and in the anamayakosha (gross body) so as to strengthen and stabilize her before she ascends to the more subtle states during meditation.

- *GOOD it is appropriate that you encourage discipline in subtle body learning for without it no true gains can arise. Only disconnectedness. - Mukunda*

We finished the session with a guided relaxation in savasana. I used a 20-25 min meditation, which brought her from the guru chakra (3rd eye) down to the heart chakra. We entered the cave of the heart into a garden with a pond and a lotus floating in the pond. She sat at the edge of the pond and contemplated 8 leaves that surrounded the lotus. On each leaf was a light that she

focused on sequentially. Each leaf represented a different element or symbol, earth, water, fire, air, fire, space, masculine-sun, feminine-moon. At each leaf we drew a link between the element and its manifestation in our individual self. Finally in the center of the lotus was a flame that drew us into a radiant light in a vast calm space. Gradually we pulled back to the lotus, the garden, to the heart and then left the heart and returned to the guru chakra to finish. I liked this meditation because it gave Linda a sense of how to progress from the gross to subtle in an ordered and systematic manner and then to return to the gross body.

- *IS OK FOR brief practice but such experiences should not be shown as the solid path for here there is no solidity. Only ether element is here and path becomes unique from individual to individual and soul has its own destiny not to be known by another. Remember the teachings the three aspects-known, unknown and Unknowable. The effort spent in seeking the latter is the true spiritual path. It is ultimately only naturally arising and achieved from detachment to all else. All is going well. Blessings. mukunda*

Fawn did some cranial sacral work during parts of the meditation. The energy from the three of us working together was powerful and Linda acknowledged feeling some of the transformational effects of the work. Coming out of savasana I had her place her hands on her chest in yoni mudra.

I summarized for Linda and Fawn added comments about the disordered and violated states of the lower charkas and the necessity for stabilizing those areas in asana and pranayama before “escaping” to the higher chakras.

Robert

2.a. Name and Description of Condition

One consequence of the evolution of man into a bipedal animal is the concentration of all the body’s weight onto the ankle joints. The relatively narrow area but wide range of mobility of these joints makes them a prime target for injury. In the US approximately 3600 cases per 100,000 people are reported annually (Taylor, Talofibular ligament Injury, 2005). During walking or running, the body’s entire weight will be placed entirely on one ankle. Walking or running on an unstable surface or in unsupported shoes can lead to forced ankle inversion and excess lateral motion in the joint that may damage the lateral ligament complex.

The degree of injury depends on the position of the ankle and the force exerted on it at the time of injury. The ankle is at highest risk when it is plantar flexed because there is less bony stability at the talocrural joint than when the ankle is in dorsiflexion. The injury may involve both the lateral ligament complex and the peroneal tendons. Repeated inversion injury can lead to chronic pain and lateral ankle instability.

2.b. Gross and Subtle Body Symptoms

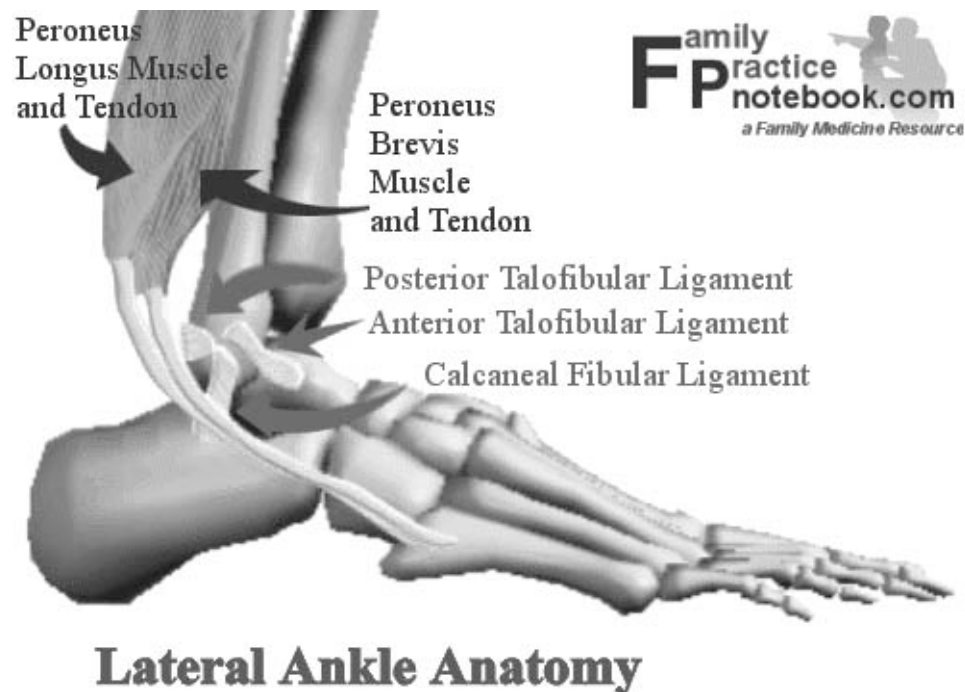
What we normally think of as the ankle is actually made up of two joints: the **talocrural joint**, and the **subtalar joint**.

The talocrural is composed of 3 bones, the **tibia** which forms the inside, or medial, portion of the ankle; the **fibula** which forms the lateral, or outside portion of the ankle; and the **talus** underneath. This joint is responsible for the up and down motion of the foot.

Beneath the true ankle joint is the second part of the ankle, the subtalar joint, which consists of the **talus** on top and **calcaneus** on the bottom. The subtalar joint allows side-to-side motion of the foot.

The ends of the bones in these joints are covered by **articular cartilage**. The major ligaments of the ankle are: the **anterior tibiofibular** ligament, which connects the tibia to the fibula; the **lateral collateral** ligaments, which attach the fibula to the calcaneus and gives the ankle lateral stability; and, on the medial side of the ankle, the **deltoid** ligaments, which connect the tibia to the talus and calcaneus and provide medial stability.

These components of the ankle, along with the muscles and tendons of the lower leg, work together to handle the stress the ankle receives as one walks, runs and jumps.



The lateral ligament complex of the ankle consists of three ligaments, 1) the anterior talofibular ligament (AFTL), the calcaneofibular ligament (CFL) and the posterior talofibular ligament (PTFL). The AFTL runs horizontally from the anterior distal fibula to insert on the neck of the talus and prevents anterior subluxation (moving out of position) of the talus when ankle is in plantar flexion. It is the weakest of the lateral ligaments. The CFL is a discrete ligament originating from the tip of the fibula and inserting downward and posterior on the calcaneus and acts as a subtalar joint stabilizer. The PTFL arises from the nonarticular surface of the posteromedial fibular and inserts onto the lateral tubercle of talus, It is strongest of the lateral ligaments and prevents posterior and rotatory subluxation of the talus.

Ligamentous injuries of the ankle are classified into three categories:

- Grade 1 – an injury without macroscopic tears. No mechanical instability is noted and pain and tenderness are minimal.

- Grade 2 – there is a partial tear, moderate pain and tenderness are present. Mild to moderate joint instability may be present.
- Grade III is a complete tear. Severe pain and tenderness, inability to bear weight, and significant joint instability are noted.

Repeated injuries indicates a tendency of the client to place the ankle in this position while walking/running without due consideration to this vulnerability. Avoiding this injury requires strengthening the joint support muscles as well as weak leg/hip muscles. Imbalances in posture emanating from the hip and leg will be projected downward to the unstable ankle and exacerbate its condition. The other key component to recovery from a weight bearing joint injury is mindfulness, not only during the short-term recovery process, but also a long-term awareness of the tendency for injury.

The vata imbalance aspects of joint injuries may lead to imbalance in the pranic body as well. In Linda's case this was readily evident in her mediation practice. Linda is keenly aware of energy movement because of her professional life as an energy healer. She felt an energy disturbance in her neck region each time she sat for prolonged meditation. In the case of Jo Anne who had an Ayurvedic assessment there were manifestations of her dosha imbalances in her lack of REM sleep and in general in the anxious state of mind she is experiencing.

2.c. Related Challenges

Athletic and physically active people are the most likely to suffer an ankle inversion injury. The initial treatment of the injury involves Rest, Ice, Compression and Elevation. During this period one must remain relatively sedentary. This is likely to be challenging for this class of people and impatience will lead to over-utilization of the injured joint. Then recurrent injury is common in the early recovery period. To prevent this an ankle support can be worn. An elastic support sock works better to stabilize the ankle than tape, which stretches and unravels. It is important that strengthening and stretching exercises be commenced in early recovery before shortening of un-utilized muscles and ligaments worsen the situation. The ankle exercises of the Joint Freeing Series are particularly helpful exercises to employ. Supplementation of the eversion exercises by pulling against a Thera-band can further strengthen the weak peroneus muscles. Ankle injury in obese people can be challenging since there is more weight concentrated on this small area and thus there is likelihood of traumatic slide slippage of the joint. It is recommended that recovering patients change from high to flat shoes to avoid possible roll-out. It is also advisable that the strengthening exercises be continued after the ankle feels 'better' in order to maintain long-term joint stability. Not following this regimen may lead to chronic ankle instability with the risk of eventual surgical management.

3. Ayurvedic Assessment

Both clients I studied had pitta or vata/pitta constitutions with different degrees of vata imbalance. Joint weakness and injury and the resultant joint pain is characteristic of imbalanced vata involving the vyana prana subdosha. The bones and joints are a target site of ama deposition in those with vata imbalances. During the initial injury phase there is also inflammation, which involves a pitta imbalance.

In the case of Jo Anne, she went to an Ayurvedic clinic for assistance. Prior to doing panchakarma they determined that she needed a preparatory rejuvenating treatment (rasayana) to reduce the presence of

ama (undigested food) in the tissues. They followed the philosophy that says “ When the patient is weak and the disease is strong, strengthen the patient and weaken the disease before doing pancha karma”. (Svoboda, Prakriti).

The panchakarma purification can weaken ahamkara and may further imbalance vata in which case the system may continue holding onto ama. Jo Anne received Triphala after pancha karma which more gently purifies the digestive system, however the panchakarma treatment may have had some adverse effects on her as evidenced by her feeling that her vata became imbalanced during the plane ride home from the treatment.

My second client, Linda, has not been professionally assessed by an Ayurvedic physician. Her vata imbalance is evident in her tendency to lose awareness of her gross body in the initial stages of pranayama or meditation sitting. This lack of grounding in the first kosha leads to disorders in her pranic kosha that manifest as mis-directed energy ascending rapidly during meditation. The energy is not organized in the lower chakras and is stimulating the throat (vishuddhi) chakra in a way that disturbs her.

Ayurvedic-based Yoga Recommendations

The Structural Yoga course of treatment for both clients followed the progression of treating in order vata , pitta, kapha and vata. After listening to their histories, the initial treatment of the perceived vata imbalances involved strengthening and stretching of the appropriate muscles in the ankle. The wider dimension of the vata imbalance in the gross body also required addressing imbalances and weakness in the leg and hip muscles above the affected ankle. The Joint Freeing Series with emphasis on the ankle and hip exercises as well as variations of selected asanas were employed. The clients used the exercises slowly with awareness and breath control. During the course of treatment both clients had to temporarily stop the program as they suffered from other maladies (knee inflammation – Jo Anne, and vertigo – Linda) that may have involved imbalances in other doshas, in particular pitta (inflammation). Time was required for these other imbalances to subside before the SYT treatment could be continued. In follow up testing towards the end of the treatment program, both clients showed significant improvement in ankle and hip strength tests.

Both clients had a prayer and mediation practice. I tried to give them better grounding in their sitting postures to help them experience the devotional (kapha) and astral state aspects of these practices. Finally, in the case of Linda, we were able to open access too the deeper koshas in a systematic approach using a guided mediation practice.

4. Common Body Readings/Findings

Relevant muscle imbalances revealed by posture include muscles supporting the feet, legs and hips. Relevant common body readings (Structural Yoga Therapy page 103):

Postural Change	Tight Muscles	Weak Muscles
Feet Turned Outward	Psoas, Ext. Hip Rotators, Sartorius, Gluteus Maximus	TFL, Gluteus Minimus
Feet Turned Inward	TFL, Gluteus Minimus	Psoas, Ext. Hip Rotators, Sartorius, Gluteus Maximus
Pronated Ankles	Peroneus Longus/Brevis	Ant/Post Tibialis
High Arch	Ant/Post Tibialis	Peroneus Longus/Brevis
Flat Foot	Ant. Tibialis	Post. Tibialis
Knock Knees	Adductors, Gluteus Medius	Gluteus Medius, TFL
Bowed Legs	Gluteus Medius, TFL	Adductors, Gluteus Medius
Tibial Torsion	TFL, Gluteus Medius	Gluteus Max, Sartorius, Tibialis Ant.
Hip Elevated	Quadratus Lumborum, psoas	same as opposing side
Hip twisted	Abdominis Oblique, Psoas, tensor fascia lata, sartorius	same as opposing side

5. Contraindicated – Modify or Eliminate

In the immediate post-trauma period prolonged weight bearing on the injured ankle must be avoided. As such the standing asanas would not be appropriate. The Joint Freeing Series is particularly useful at this time for strengthening and stretching the foot, leg and hip muscles.

During latter recovery stages the standing asanas can be progressively introduced to build weight-bearing strength in the ankle joint. At first, the wall or a chair may be required to assist in the balancing aspects of the standing asanas. The client should not challenge their ankle weakness by falling out of a balancing asana, this could lead to inadvertent re-injury. Through progressive strengthening above the ankle joint the client may eventually achieve a stable tree pose on the injured foot.

6. General Recommendations

Long term maintenance of ankle stability requires a regular program of ankle, leg and hip strengthening exercises and asanas. Ankle rotation and eversion strengthening actions are required.

Therapeutic/Free of Pain:

- Post-Traumatic period – address pitta imbalance aspect – reduce joint swelling: Follow Rest, Ice, Compression and Elevation (R.I.C.E.) of the ankle.
- Address vata imbalance aspect – reduce joint pain and work on joint ROM and joint strength recovery: Do the Joint Freeing Series with emphasis on slow aware movements using the breath

and emphasizing the ankle and hip exercises. Stretch and release the posterior tibialis through body work.

Stabilize the Situation:

- Wear an elastic ankle brace to support the ankle during walking. Do not jump or run for a few weeks. Continue the JF Series and begin to add standing postures but not balancing postures yet. Work on maintaining posture holding, not moving quickly from posture to posture. This will continue to address the vata imbalance in a progressive manner.
- Emphasize frequent ankle ROM exercises during the day, particularly eversion movements. Avoid unaware inversion movements.
- Modify the seated meditation posture so that the ankle is not in the inverted position. Prolonged seated postures with ankle inversion can lead to re-injury!

Maintenance:

- Continue with the JFS emphasizing hip and ankle. To the standing posture, add balancing postures such as Tree Pose. Standing sequences such as the Palm Vinyasa (see Appendix) are useful because they are rooted in Tadasana.
- Deeper work on Vata imbalance should be addressed, All seated pranayama and meditation should be grounded in a well structured active seated posture since the tendency here is to lost track of the annamayakosha. Vata imbalance dietary changes should be considered: see Prakriti (Svoboda) and Radical Healing (Ballentine) references.

7. Questions and Answers from www.yogaforums.com

Knock Knees

☐ Posted: Thu Aug 05, 2004 6:44 am Post subject:



the exercises i did for my knock-knees was prolonged Virabhadrasana II and countered with trikonasana. The details of my transformation are given in my book Structural Yoga Therapy. It outlines what muscles need to stretched and strengthened for all postural conditions then also names poses to work in. The key is to feel the specific muscles in the poses not the poses themselves. Blessings on your sadhana. Mukunda

Weak Ankles

☐ Posted: Sun Sep 19, 2004 7:48 am Post subject:

For the ankles, in addition to practicing Joint Freeing Series, you can practice your standing poses while you pay attention to the weight distribution in your feet. Without more information, I cannot evaluate which muscles of the lower leg may be involved. Do you have a low or a high arch? Often, there is a falling toward center or dropping of the arch associated with **weak** ankles. Lifting the toes off the ground during standing poses is helpful to rebalance the action of the lower leg muscles. You can also practice standing on tip toes, and coming into a knee bend while on tip toes to improve stability of the **ankle**. Namaste, Chandra

Ankle Iversion/Eversion

Posted: Wed Apr 24, 2002 5:59 pm Post subject:



Hip flexors are toned by doing leg lifts, single is safest. Bridge pose lowering slowly, warrior II, boat pose (Navasana) also tones them. In my Joint Freeing Series (described in detail on page 137 of Structural Yoga Therapy), the second motion is dorsiflexion with **ankle** eversion. In this motion the toes are pulled toward the head (dorsiflexion) and the anklebones are brought together with the outside edges of the feet pulled toward the head (eversion). The muscles that are toned are the peroneous longus and brevis. If the motion cannot be done then the antagonist muscles performing the opposite motion are tight. The Opposite motion is **ankle** inversion in which the soles come together mimicking namaste of the hands. The muscles contracting to do this are the posterior tibialis. This is the motion of the back foot in Virabhadrasana I and II and Trikonasana. It is commonly a **weak** movement requiring the teacher to remind the student to lift the inner **ankle**. Practice, practice, practice and look diligently at an anatomy atlas to identify the muscle within your student's body.

Foot Injury – Tight IT Bands

Posted: Wed Oct 27, 2004 8:19 am Post subject: Foot Injury



I have, from the right broken foot episode: Plantar fasciitis, **ankle** tendonitis (the tarsel tunnel is about gone) in right foot; bursitis in left hip but both hips sort of lock up when standing up if i sit very long - even in a chair. I have some ulnar nerve damage in wrists and some thumb pain from using crutches. And my chondromalasia in my knees is kicking in big time. I have continued my exercises you gave me from my first private with you plus JFS and sacral freeing work as well as all the stuff the pts have given me. I don't even have the time or the strength to go through an entire regular yoga session anymore. After being in physical therapy for 3 months, i opted for a cortazone shot in my left bursa which has relieved most of the pain there and my gate is less altered.

I noticed in the questions a reference to stretching the IT band ... critical for chondromalasia and the hip problems I am having. The only thing pt is giving me is leg "hang-overs." laying on my side with the top leg hanging over behind me and psoas stretches holding one knee while the other leg hangs off the edge of the table. I have done side stretches (bend to tight with left leg and foot placed behind the right). Because i am generally pretty flexible - none of these really seem to "get into the IT band.

Posted: Wed Oct 27, 2004 8:20 am Post subject: Foot Injury Reply



For stretches to the IT band there are several alternatives what was given for you is the mildest of the possibilities. Moderate stretch can be done by standing side bend pushing out on the side of the hip joint to stretch the IT; one often needs to slightly rotate the pelvis for it to catch where you are tight. Another alternate is revolving head to knee pose (Parivrtta Janu Sirsasana). For most people this stretches the lumbar sacral fascial band but in some cases the pull will extend down the outer pelvis to the IT. Both these are a try it and see. The most intense IT stretch I have found is to sit in eagle pose (Garudasana), legs only and lay backward while attempting to keep knees stacked and close to the floor. On some by leaning forward with the same leg pose it will move to the IT; thought most feel it in the gluteus medius muscle. To my way of thinking stretching either is a good idea as the IT band attached to the gluteus medius, gluteus maximus and tensor fascia lata hence any stretch that affects any of these muscles will with relaxation to into the IT band.

Ankle Supination (Inversion)

Posted: Sun May 09, 2004 11:28 am Post subject: asana positions to help with supination of my feet



Hello

I supinate my feet (roll outward) and would like to fix that through asana if possible. Could anyone give me

insight into what poses may be most helpful and/or any other information on supination that may help me.
Thank you very much.
Blessings,
Lunalotus

Posted: Tue May 18, 2004 10:59 am Post subject:



Dear Lunalotus,

Want first to be clear. I think you are referring to having a high arch, or holding most of the weight of the body on the outer edges of the foot. When carried further, this would lift the big toe off the floor and bring the soles of the feet toward one another. (If done from sitting in Stick pose, this motion brings the feet into "Namaste"). This movement is called Inversion, and the prime mover is the Anterior Tibialis, which comes along the front of the shin and curls under the foot creating the arch of the foot. A more common condition is called ankle pronation, or inversion, where the arch drops. (If done from sitting in Stick pose, this motion brings the little toes toward the head).

If so, you could experiment with stretching the Anterior Tib and strengthening the antagonist muscles on the outer side of the lower leg, Peroneus Longus and Brevis.

Ways to do this are awareness of balance of weight across the feet in Mountain pose, followed by coming to tip toes, followed by a slow squat, paying attention to maintaining the weight distribution across the foot. You can also sit in Hero pose, big toes and heels touching, to stretch the Anterior Tib. Joint Freeing Series is described in Mukunda's book Structural Yoga Therapy and you may benefit from including the movements described for the ankle. These include inversion, eversion, flexion, extension and circumduction of the ankle from Stick Pose. All of the standing poses can be used to investigate the way you balance your weight across the foot, and can be a launching point for balancing the effort of the muscles noted.

hope this helps - you can also do a search of this site for more recommendations for ankles. Possible search words are feet, arches, ankles...

Namaste!
Chandra

Posted: Wed Apr 24, 2002 5:54 pm Post subject:



I also want to thank you for the question and answer service you provide. It has been very helpful to me to be able to get answers to my questions, also to hear other's questions answered. In regards to the lunging forward on the sun salute, what are some ways of strengthening the hip flexors? Another question if I may: In the joint freeing exercises, one of my students can roll her feet so that the soles meet, but she can't do the opposite at all. What would inhibit that action, and what would be the consequence of not being able to do that? What I was talking about is the joint freeing exercise in Dandasana where you roll the feet (pronation?), first so that the soles come together, then the big toe side stretches away as the pinkie side comes toward you so that the soles of the feet are on the outside (supination?). This is the action that my student cannot get. Thanks again, Hiyalah.

Posted: Wed Apr 24, 2002 5:59 pm Post subject:



Hip flexors are toned by doing leg lifts, single is safest. Bridge pose lowering slowly, warrior II, boat pose (Navasana) also tones them. In my Joint Freeing Series (described in detail on page 137 of Structural Yoga Therapy), the second motion is dorsiflexion with ankle eversion. In this motion the toes are pulled toward the head (dorsiflexion) and the anklebones are brought together with the outside edges of the feet pulled toward the head (eversion). The muscles that are toned are the peroneous longus and brevis. If the motion cannot be done then the antagonist muscles performing the opposite motion are tight. The Opposite motion is ankle inversion in which the soles come together mimicking namaste of the hands. The muscles contracting to do this are the posterior tibialis. This is the motion of the back foot in Virabhadrasana I and II and Trikonasana. It is commonly a weak movement requiring the teacher to remind the student to lift the inner ankle. Practice, practice, practice and look diligently at an anatomy atlas to identify the muscle within your student's body.

Mukunda

Ankle Eversion

Posted: Sun May 09, 2004 11:28 am Post subject: asana positions to help with supination of my feet



Hello

I supinate my feet (roll outward) and would like to fix that through asana if possible. Could anyone give me insight into what poses may be most helpful and/or any other information on supination that may help me. Thank you very much.

Blessings,
Lunalotus

Posted: Tue May 18, 2004 10:59 am Post subject:



Dear Lunalotus,

Want first to be clear. I think you are referring to having a high arch, or holding most of the weight of the body on the outer edges of the foot. When carried further, this would lift the big toe off the floor and bring the soles of the feet toward one another. (If done from sitting in Stick pose, this motion brings the feet into "Namaste"). This movement is called Inversion, and the prime mover is the Anterior Tibialis, which comes along the front of the shin and curls under the foot creating the arch of the foot. A more common condition is called ankle pronation, or inversion, where the arch drops. (If done from sitting in Stick pose, this motion brings the little toes toward the head).

If so, you could experiment with stretching the Anterior Tib and strengthening the antagonist muscles on the outer side of the lower leg, Peroneus Longus and Brevis.

Ways to do this are awareness of balance of weight across the feet in Mountain pose, followed by coming to tip toes, followed by a slow squat, paying attention to maintaining the weight distribution across the foot. You can also sit in Hero pose, big toes and heels touching, to stretch the Anterior Tib. Joint Freeing Series is described in Mukunda's book Structural Yoga Therapy and you may benefit from including the movements described for the ankle. These include inversion, eversion, flexion, extension and circumduction of the ankle from Stick Pose. All of the standing poses can be used to investigate the way you balance your weight across the foot, and can be a launching point for balancing the effort of the muscles noted.

hope this helps - you can also do a search of this site for more recommendations for ankles. Possible search words are feet, arches, ankles...

Namaste!
Chandra

8. References

Ballentine, Rudolph & Funk, Linda; **Radical Healing : Integrating the World's Great Therapeutic Traditions to Create a New Transformative Medicine**, Three Rivers Press, 2000.

Gorman, David, **The Body Moveable**, Canada p 126-158, ISBN 1-903518-15-6, 1981.

Jenkins, David B. & Hollinshead, W. Henry, **Hollinshead's Functional Anatomy of the Limbs and Back**, W.B. Saunders Co, 2002

Schuenke, Michael MD, PhD, Schulte, Eric MD et al., **Thieme Atlas of Anatomy**, Thieme, 2006

Svoboda, Robert, **Prakriti: Your Ayurvedic Constitution**, Lotus Press, 1998.

Stiles, Mukunda, **Yoga and Ayurveda** – Draft, personal communication, 2005

Stiles, Mukunda, **Structural Yoga Therapy – Adapting to the Individual**, Weiser Books, 2001

Internet References

American Family Physician – Online – Information from Your Family Doctor – **How to Care for Your Ankle Sprain**, 1998

www.blackburnfeet.org.uk/hyperbook/conditions/ankle%20instability.htm, **Management of Chronic Ankle Instability**.

<http://www.blackburnfeet.org.uk/hyperbook/trauma/ankle%20ligament%20injuries.htm>, **Management of Acute Ligament Injuries**.

Encyclopedia of Sports Medicine and Science – Online, **Ankle Acute Injuries**, Karim Khan & Peer Bruker 1998

JointHealing.com, **Foot and Ankle Anatomy & Chronic/Acute Ankle Sprains**.

The Physician and Sportsmedicine – online, **Persistent Pain after Ankle Sprain: Targeting the Causes**, Hugh L. Bassewitz MD and Matthew S. Shapiro MD, 1997.

www.epodiatry.com/ankle-sprain.htm

www.emedicine.com/sports/topic126.htm, emedicine – **Talofibular Ligament Injury**, Michael Taylor MD & David Martin MD, 2005.

www.emedicine.com/sports/topic126.htm, **Calcaneofibular Ligament Injury**, Bryan L. Reuss MD & Michael C. Wadman MD, 2005.

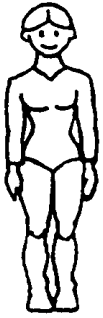
www.fpnotebook.com/ORT56.htm - **Lateral Ankle Ligament Diagram**

9. Appendix

The Palm Vinyasa sent by Mukunda. See following page.

Palm Tree Vinvasa

Tadasana



1-Mountain Pose
Tadasana



2- INHALE, upward salute. EXHALE-outward fingerlock



3- INHALE, raise heels balancing in Palm Tree Pose. EXHALE, down INHALE, stretch up



4- EXHALE, side bend



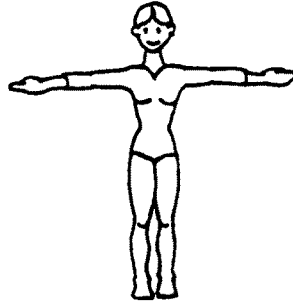
5- INHALE, center Not shown opposite side bend



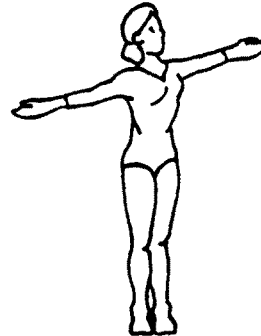
6- EXHALE, twist & look up.



7- INHALE, center Reverse twist.



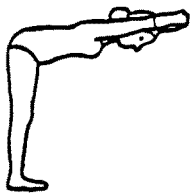
8- EXHALE, lower arms INHALE turn palms up



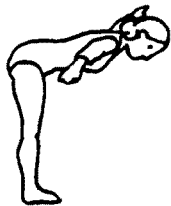9- EXHALE, twist look at thumb Reverse twist



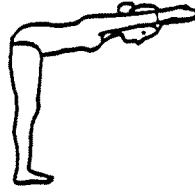
10- INHALE, lace fingers outward fingerlock



11- EXHALE, half forward bend



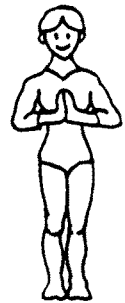12- INHALE, spread arms across



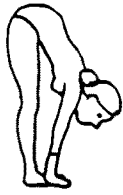13- EXHALE, arms forward in Namaste.



14- INHALE, erect



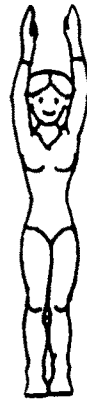15- EXHALE center Mountain Pose



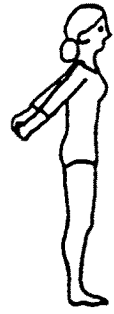15- EXHALE, palms to floor beside feet. INHALE, arch back, head up.



16- EXHALE, head to legs in Intensive Stretch Pose Uttanasana



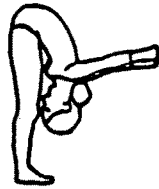
17- INHALE, raise up arms overhead



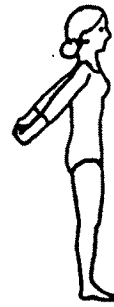18- EXHALE, interlace fingers behind back Pose of Karma - Karmasana



19- INHALE, squeeze shoulders and look up



20- EXHALE, forward bend pulling arms away from back.



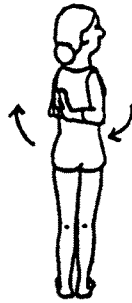21- INHALE, return to erect posture.



22- EXHALE, namaste behind back, or hold elbows



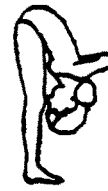23- INHALE, head up



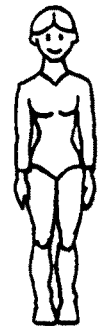24- EXHALE head level as you turn right INHALE, center EXHALE, to left INHALE, center



25- EXHALE, lift chest hips firm back bend looking up. INHALE, center.



26- EXHALE, gentle forward bend.



27- INHALE, center EXHALE, lower arms return to Mountain Pose